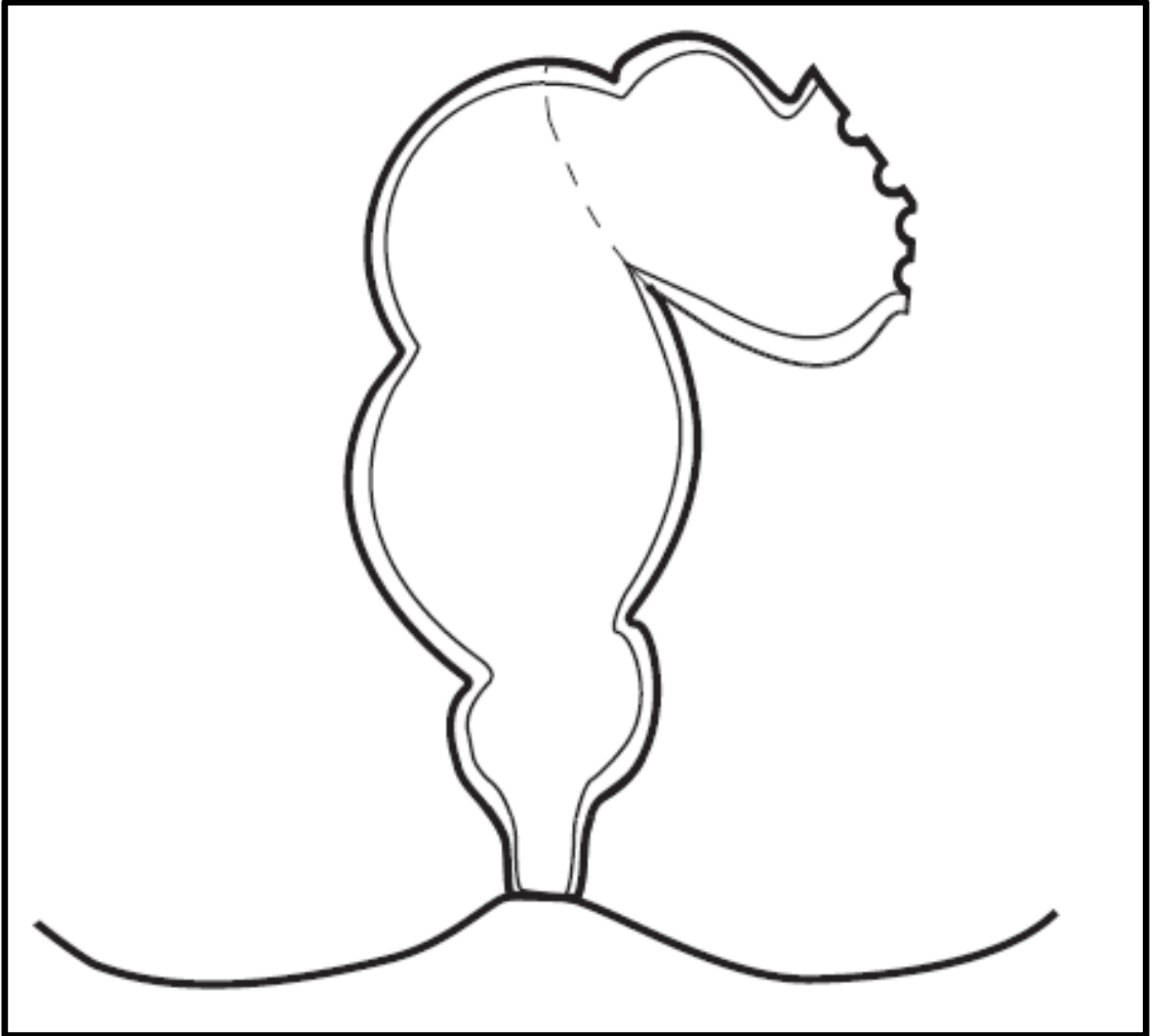
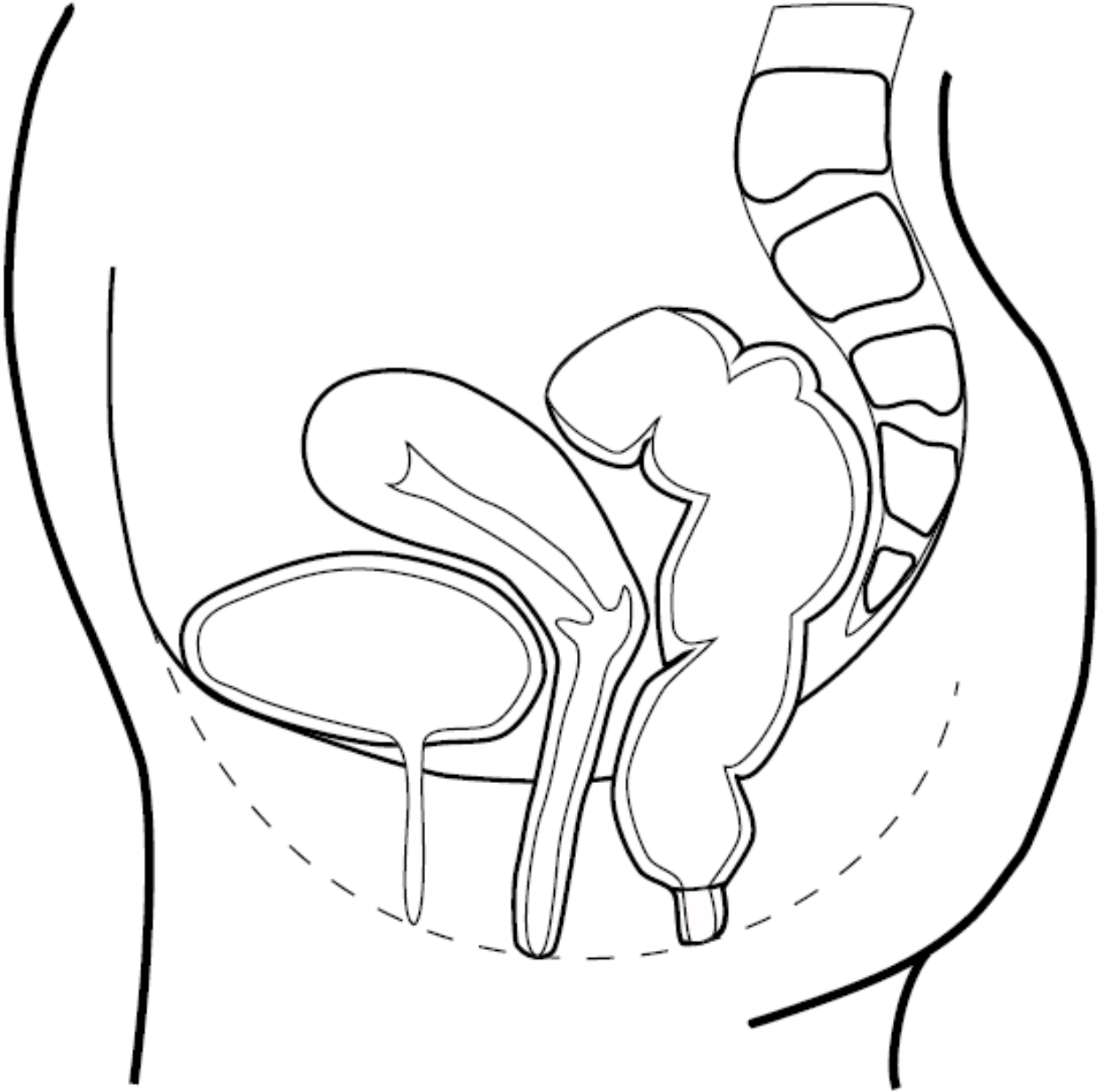


Rectal Anatomy and Rectal Cancer Staging Printouts

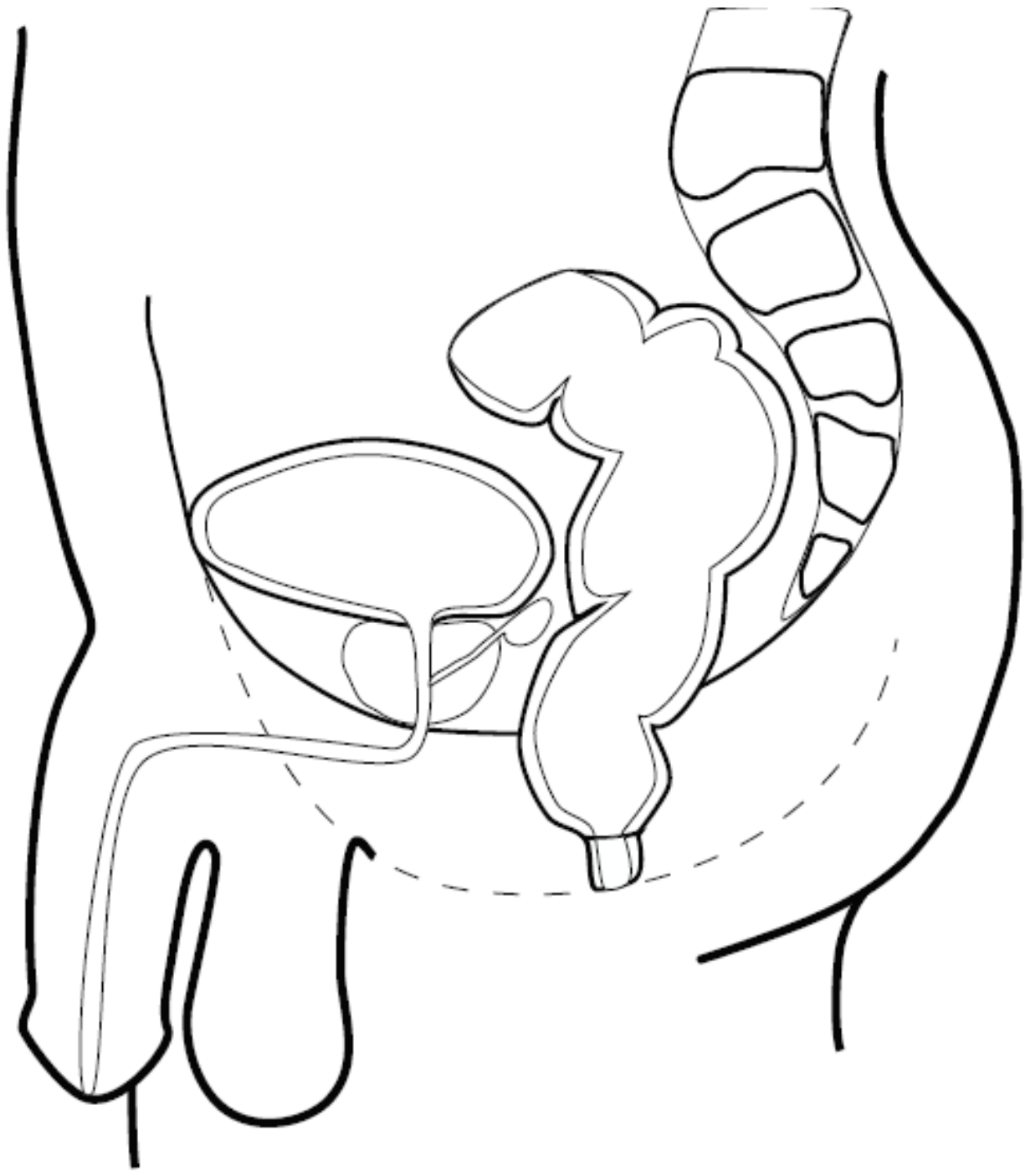
Front (Coronal) View of the Rectum



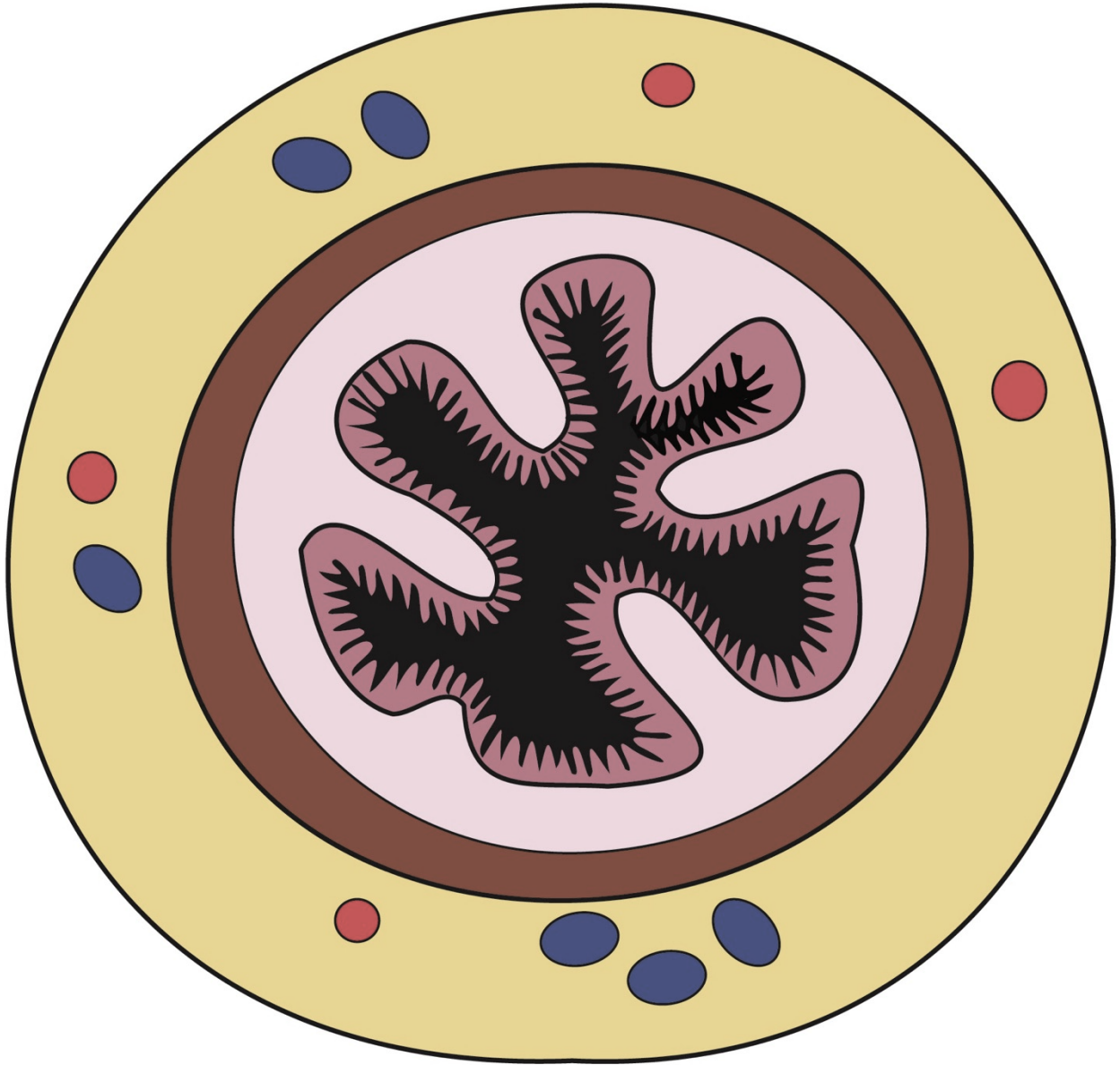
Side View (Sagittal) of an Adult Female



Side View (Sagittal) of an Adult Male

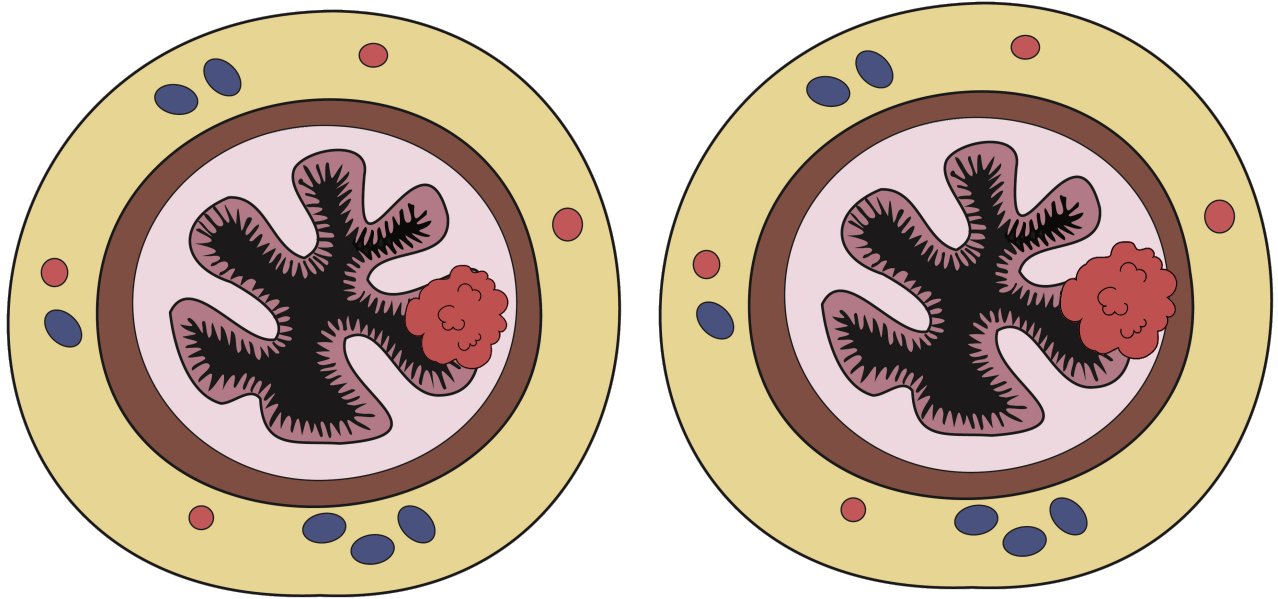


Cross-section of the Rectum




Questions I Have

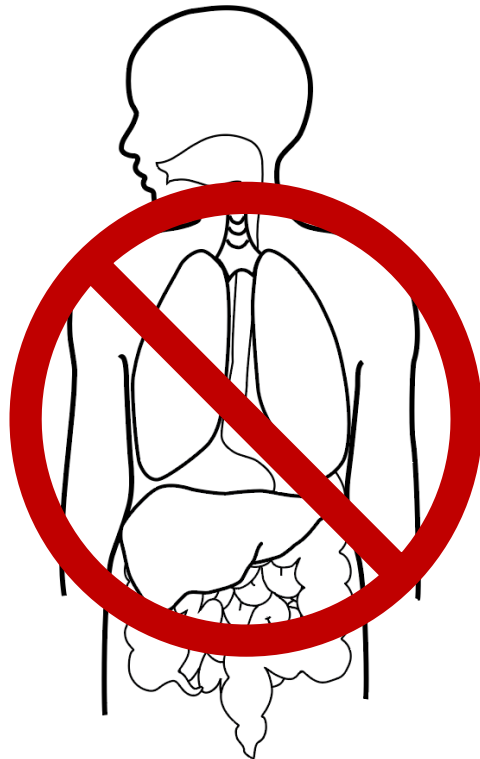
Rectal Cancer - Stage 1



Tumor Between the Lining and the Muscle Layer in the Rectum

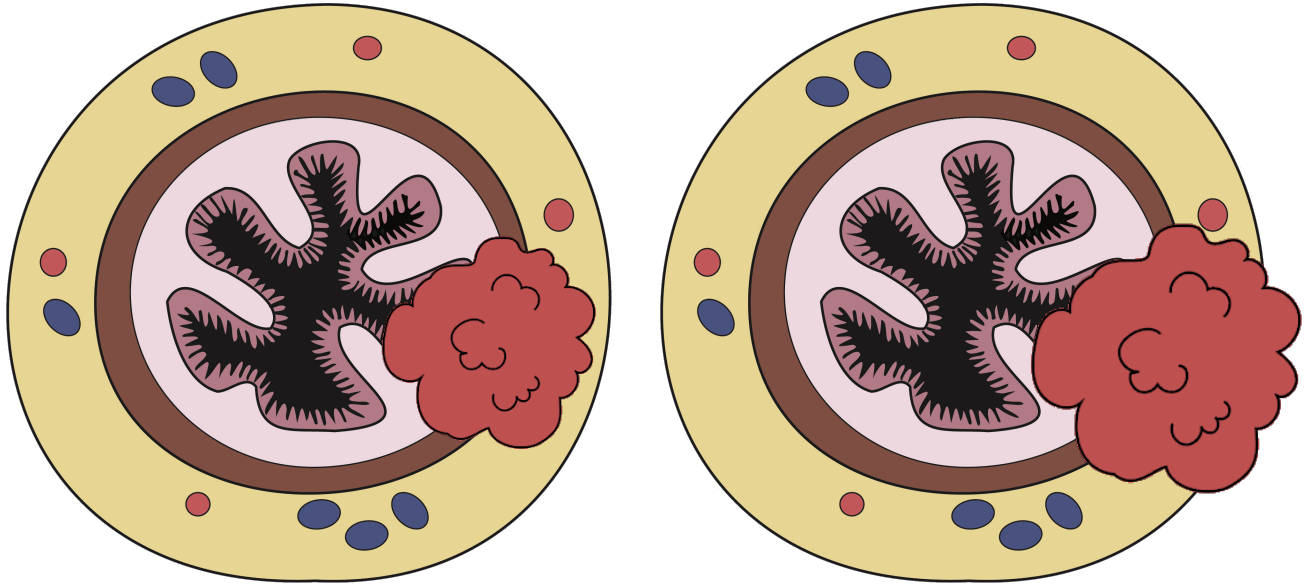


No Cancer in Lymph Nodes




No Spread

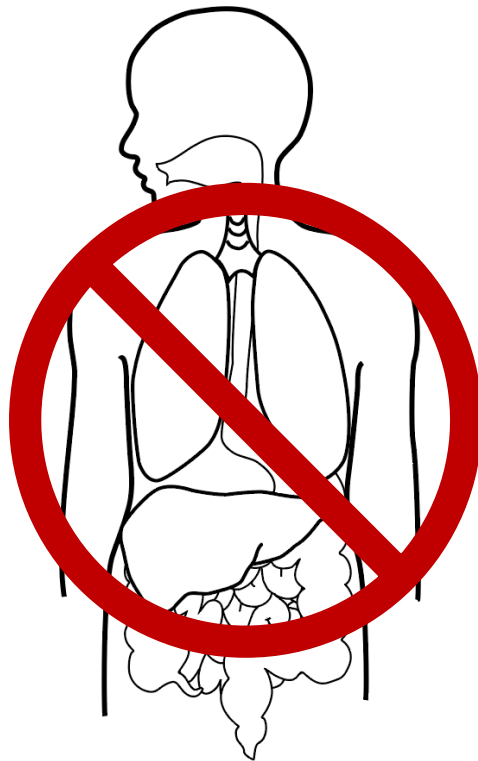
Rectal Cancer - Stage 2



Tumor into the Fatty Covering of
the Rectum or Beyond

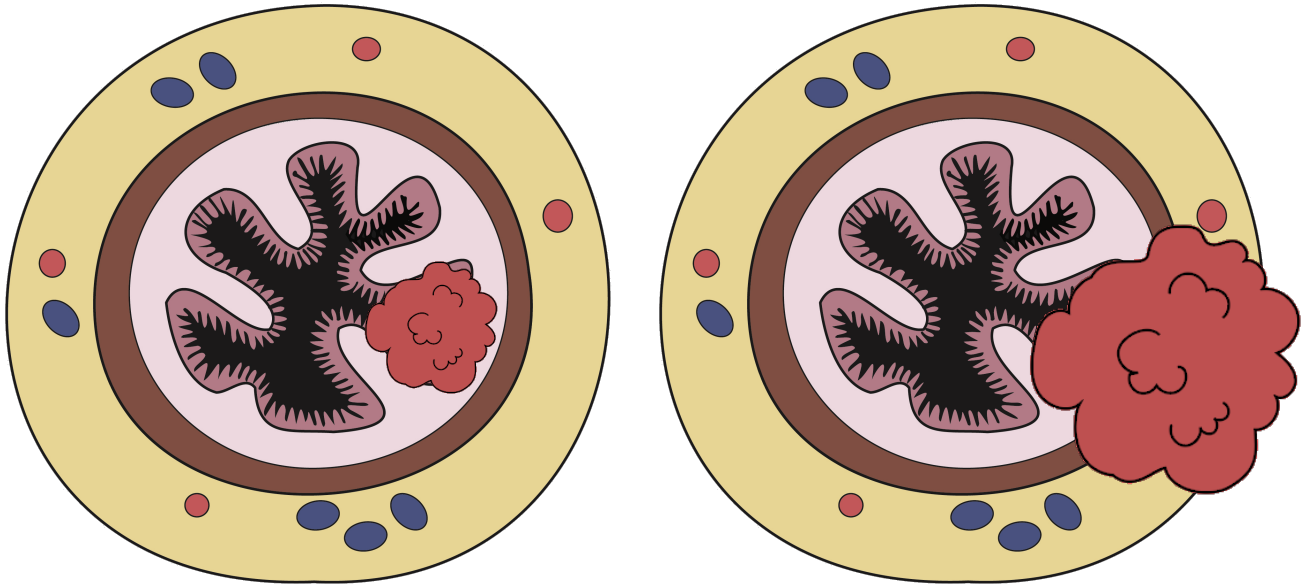


No Cancer in Lymph
Nodes

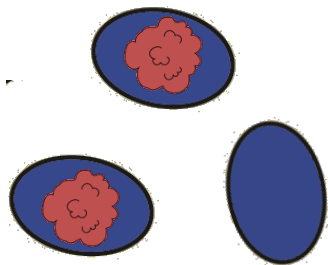


No Spread

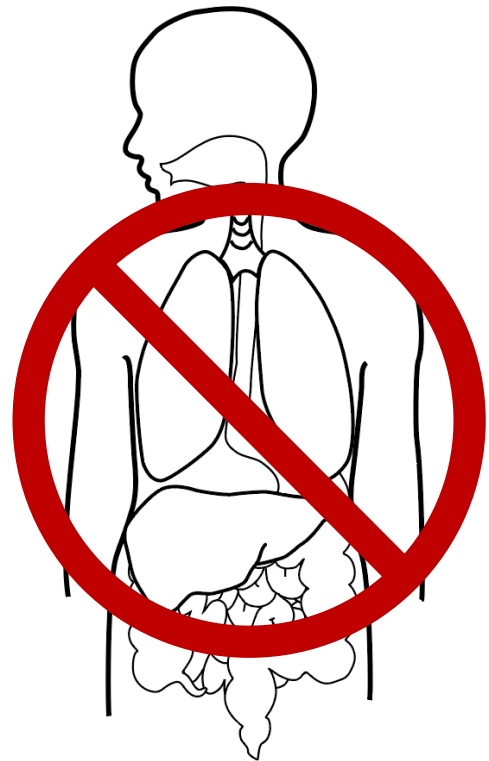
Rectal Cancer - Stage 3



Any Tumor Depth

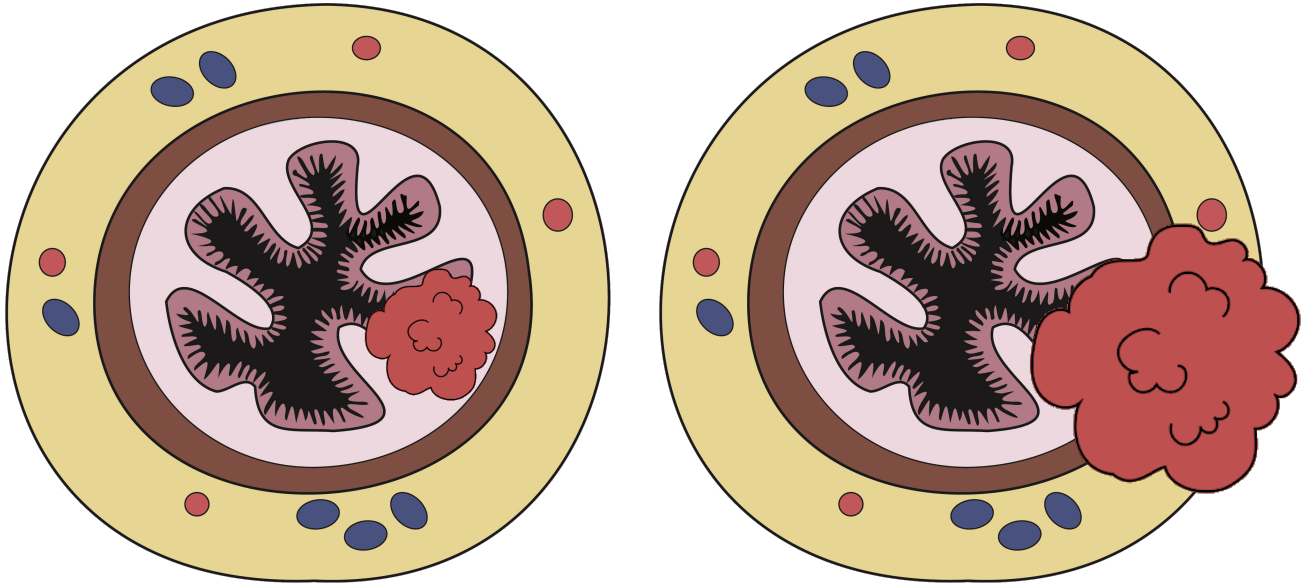


Cancer in Lymph Nodes

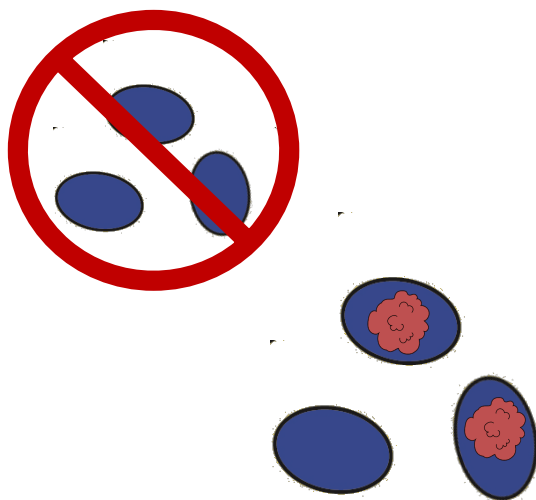


No Spread

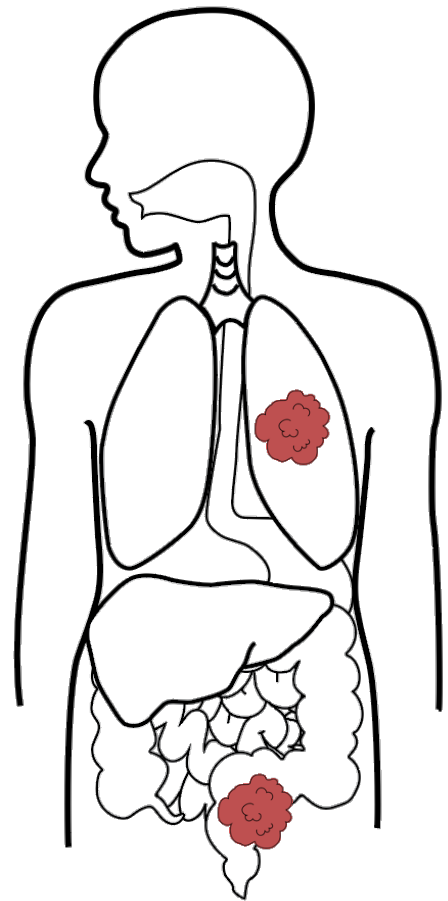
Rectal Cancer – Stage 4



Any Tumor Depth

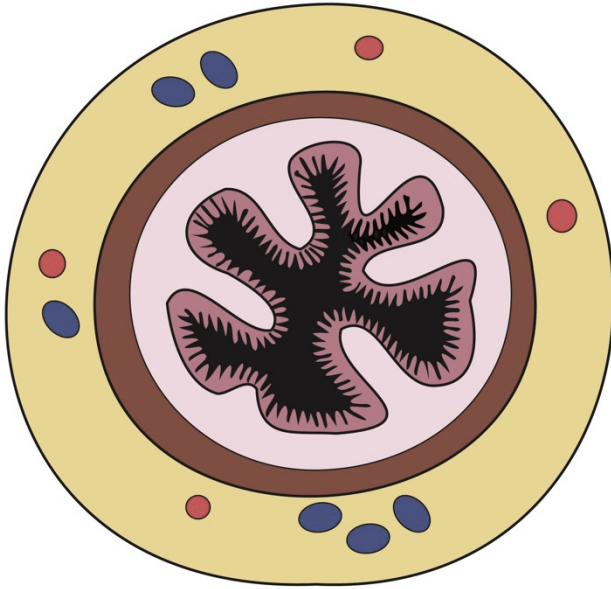


Any Lymph Node Status




Spread Outside
the Rectal Area

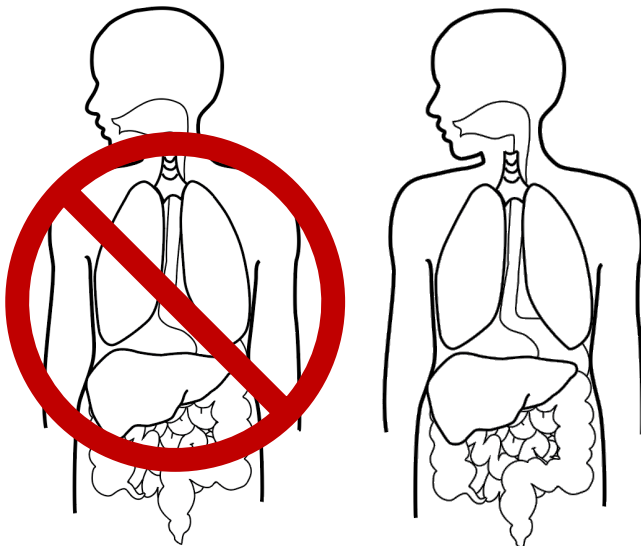
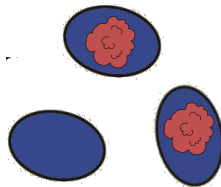
My Stage _____



Tumor Depth



Lymph Node Status



Spread